

Fluoro-edenite non-neoplastic diseases in Biancavilla (Sicily, Italy): pleural plaques and/or pneumoconiosis?

Caterina Bruno^{1*}, Rosario Di Stefano², Vincenzo Ricceri³, Mauro La Rosa³, Achille Cernigliaro⁴, Paolo Ciranni⁵, Giuseppe Di Maria⁶, Daniele Mandrioli⁷, Amerigo Zona¹, Pietro Comba^{1*} and Salvatore Scondotto⁵

¹Dipartimento Ambiente e Salute, Istituto Superiore di Sanità, Rome, Italy

²Azienda Provinciale Sanitaria, Catania, Italy

³Divisione di Radiologia, Ospedale Maria Santissima Addolorata di Biancavilla, Azienda Provinciale Sanitaria, Catania, Italy

⁴Unità Operativa Complessa di Patologia Clinica, Dipartimento di Scienze Radiologiche e Servizi, Ospedale Sant'Antonio Abate, Azienda Sanitaria Provinciale, Trapani, Italy

⁵Dipartimento per le Attività Sanitarie e Osservatorio Epidemiologico, Assessorato della Salute, Regione Siciliana, Palermo, Italy

⁶Dipartimento di Medicina Interna, Università di Catania, Catania, Italy

⁷Istituto Ramazzini, Bologna, Italy

*retired

Abstract

Background. A mesothelioma cluster in Biancavilla (Sicily, Italy), drew attention to fluoro-edenite, a fibre classified by International Agency for Research on Cancer as carcinogenic to humans. Significant excesses in mortality and morbidity were observed for respiratory diseases and a significant excess of pneumoconiosis hospitalizations was reported.

Objective. Aim of this study is to assess the characters of the lung damage in Biancavilla residents hospitalized with pneumoconiosis or asbestosis diagnoses.

Methodology. Medical records, available radiographs and computed tomography scans were collected. The obtained imaging was reviewed by a panel of three specialists and focused on pleural and parenchymal abnormalities. Cases with an ILO-BIT or ICOERD score equal or greater than 2 were considered positive for a pneumoconiosis-like damage, cases with a score lower than 2 or insufficient quality of imaging were considered inconclusive. If no pneumoconiotic aspects were present the cases were classified as negative.

Results. Out of 38 cases, diagnostic imaging for 25 cases were found. Ten cases out of 25 showed asbestosis-like features, nine subjects were considered negative. In six patients' results were inconclusive.

Conclusions. Asbestosis-like features were substantiated in Biancavilla residents without known occupational exposure to asbestos. Further studies to estimate population respiratory health are required. Experimental studies on the fibrogenic potential of fluoro-edenite are needed.

Key words

- fluoro-edenite fibre
- fluoro-edenite related diseases
- environmental exposure
- health impact

INTRODUCTION

A cluster of deaths from pleural malignant tumour was reported in Biancavilla (Sicily, Italy), 23,052 inhabitants, a municipality similar to the others scattered at the slopes of Etna Volcano with large areas occupied by orange and lemon trees [1, 2]. No industrial facilities are present, with the exception of a huge quarry where rocks containing a material similar

to tuff was operating for several decades. This material was largely used in the local building industry and for road paving. No particular occupational exposures (direct or indirect) to asbestos have been reported either in Biancavilla or in the other Etnean municipalities. More specifically, no ascertained occupational exposure to asbestos was detected among the cases of mesothelioma interviewed by the investigators of the

Sicilian Mesothelioma Register in their permanent ongoing routine survey.

The researchers' attention thus focused on a quarry material containing a previously unknown amphibole, identified as fluoro-edenite [3] and considered it to be related to the disease [4]. Experimental studies *in vivo* and *in vitro* [5-7] confirmed the fibre be able to induce mesotheliomas. The International Agency for Research on Cancer (IARC), on the basis of the mesothelioma incidence data in Biancavilla [8] and the aforementioned experimental data, classified fluoro-edenite as carcinogenic to humans (Group 1, sufficient evidence of carcinogenicity in humans) [9].

Epidemiological studies on the resident population carried out in order to detect the other diseases possibly related with exposure to the fluoro-edenite fibres [10] found out an excess of mortality from chronic obstructive pulmonary diseases.

Statistically significant excesses in mortality and morbidity were observed for respiratory diseases both in men and women [11], and a significant excess of hospitalization due to pneumoconiosis was reported [12-14].

Pleural plaques and lung parenchymal lesions were detected in 43 construction workers, all men, exposed to fluoro-edenite in Biancavilla. Pleural bilateral plaques were detected in 39 subjects out of 43, fibrosis was present in seven workers and a restrictive ventilatory defect in two subjects [15].

A retrospective cross-sectional study in inhabitants of Biancavilla exposed to fluoro-edenite, compared with a population living and working at least 30 km away from Biancavilla was performed, to assess the occurrence and the prevalence of pleural plaques. High-Resolution Computed Tomography (HRCT) chest scans carried out in Biancavilla municipality hospital site (exposed subjects) were compared with HRCT chest scans carried out in a hospital 30 km away from Biancavilla. The relative risk (RR) for pleural plaques in the "exposed" population was 6.74 CI 95% (4.47-9.58). Lung parenchymal abnormalities were observed in 11% of exposed group (fibrosis = 8%) vs 1% in the unexposed subjects (fibrosis = 0.5%) [16].

The aim of the present study was to assess the distinguishing characters of pleural and/or parenchymal damage, in resident in Biancavilla subjects, hospitalized and diagnosed with "pneumoconioses" in any part of the hospital discharge form, since pneumoconiotic diseases are unexpected in non-occupationally exposed populations.

MATERIALS AND METHODS

The present study comprises the series of residents in Biancavilla hospitalized since January 2006 to December 2013 in the Sicilian Region and diagnosed with "pneumoconioses or other lung diseases due to external agents" (500-508 codes, 9th revision of International Statistical Classification of Diseases, ICD) in any part of the hospital discharge form.

Medical records were searched for, and the available radiographs and Computed Tomography (CT) scans were collected. If available, additional personal information on patients was collected through family doc-

tors. Unfortunately, lung function tests were not available for a revision because of technical issues (faded thermal paper).

The obtained imaging was reviewed by a panel of three specialists (two skilled radiologists and one epidemiologist and occupational physician) and focused on pleural and parenchymal abnormalities. The panel was unaware of diagnoses reported in the personal records.

The International Labour Office-Bureau International du Travail (ILO-BIT) [17] criteria for the radiographs and the International Classification of HRCT for Occupational and Environmental Respiratory Diseases (ICOERD) [18] for CT scans were utilized.

We classified the results in a semi-quantitative approach considering positive for a parenchymal pneumoconiosis-like damage cases with an ILO-BIT or ICOERD score equal or greater than 2. Cases with score lower than 2 or with insufficient quality of imaging were classified as "doubtful cases". If no pneumoconiotic aspects were present or no parenchymal damage was found, the cases were classified as negative.

The study was performed in accordance with the Declaration of Helsinki of the World Medical Association [19] and the name and all birth/personal data were anonymised and each subject had a code assignment.

RESULTS

Thirty-eight patients were hospitalized in the observed period. One infant with aspiration pneumonia was excluded from the case series. Out of the 37 remaining patients, medical charts were recovered for 34 subjects (21 men and 13 women), aged between 42 to 88 (Figure 1).

The main cause of hospitalization was related to respiratory diseases in 26 patients, one being affected by mesothelioma, 12 recovered for asbestosis, one for silicosis, and two for unspecified pneumoconioses. One patient was hospitalized for ICD code 506 (respiratory conditions due to chemical fumes and vapours) and two of them for ICD code 507 (pneumonitis due to solids and liquids). Including the secondary diagnoses, asbestosis was reported in a total of 25 cases, pneumoconiosis due to silica and other silicates (silicosis) in three cases, and unspecified pneumoconiosis in two cases. Other main causes related to respiratory disease were pleuritis (one case), acute respiratory failure (three cases), and other respiratory abnormalities (two cases).

In 12 cases (6 men and 6 women) no diagnostic imaging were obtained, average age was 73.8 in men and 68.7 in women. Little information was found on previous occupations in two men (a quarryman and a house painter) in this group.

Diagnostic imaging to be examined by the panel were available for 25 cases (19 men and 6 women). Chest Rx were found for 10 subjects and CT scans for 19 patients (all but four have been subjected to both examinations).

In all subjects, pleural plaques were found, most of them (22 out 25) were calcified. All available images pointed to a diagnosis of asbestosis-like disease with diffuse and bilateral pleural plaques, very rare in silicosis. Subjects included in the study with a diagnosis of "aspiration pneumonia" also presented pleural plaques.

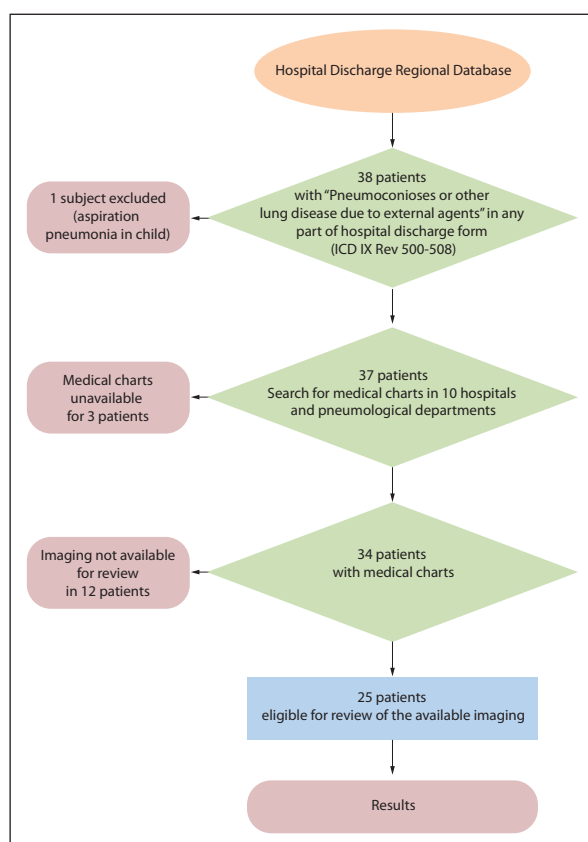


Figure 1
Selection of cases eligible for imaging review, flow chart.

Ten cases out of 25 showed asbestosis-like parenchymal features, nine subjects presenting lung alterations not related to pneumoconiosis or not presenting parenchymal damage were considered negative for imaging results. In further six patients imaging results were inconclusive because of insufficient quality or characteristics of imaging (Table 1).

In Table 2 cases with parenchymal features suggestive for asbestosis-like pneumoconiosis with ICOER or ILO-BIT score equal or greater than were itemized. Average age was 63.1 (66.1 in men and 50 in women).

The negative cases were six men and three women: in four people no parenchymal damage was found (two men and two women); one man and one woman presented a CT suggesting old tuberculosis scar; two men were affected by mild emphysema and one man presented increased broncho-vascular markings and hyperlucency of lung middle zones. Average age was 57.6 (55.2 in men and 62.3 in women) (Table 3).

Cases presenting some features of pneumoconiotic damages but imaging characteristics insufficient for a definition of asbestosis-like pneumoconiosis were itemized in Table 4. Average age was 66.3 (64.4 in men).

DISCUSSION

In asbestos exposed workers the occurrence of asbestosis is related to an intense exposure (at least 25/fibres/mL/year) [20] with very few case studies reporting parenchymal fibrosis of the lung due to environmental exposure to asbestos [21, 22].

In Italy hospital discharge records are classified according to the International Statistical Classification of Diseases, 9th revision [23] and pleural plaques were not included as an item like in the 10th revision [24].

It is for that reason that we considered the possibility that pneumoconioses and asbestosis codes were utilised to encode merely pleural plaques or other pleural alterations commonly found in population environmentally exposed to asbestos [25-27] or other natural fibres [21, 22, 28]. Furthermore, we did not exclude other diseases, e.g., "inhalation pneumonia", that could be misclassified in other similar codes. For these reasons we decide to include in the analysis all the residents in Biancavilla, hospitalized in Sicily diagnosed with any disease included in "pneumoconioses or other lung diseases due to external agents" in any part of the hospital discharge form.

The Sicilian protocol about surveillance on asbestos exposed and former exposed subjects [29] provides chest radiographs as first level diagnostic exams, in accordance with the procedures of the ILO-BIT for the pneumoconiosis established by an international team [17] and updated by the Helsinki criteria update in 2014 [18]. Most of our recovered cases had undergone further medical examinations and were submitted to CT scan of the chest.

Chest radiographs were available in few cases, but with sufficient technical quality, except one case having only the postero-anterior projection, not sufficient for the ILO-BIT criteria for a pneumoconiosis diagnosis.

In our study most of CT scans presented a sufficient quality for the ICOERD criteria for imaging reading for pneumoconiosis. Reliability of the ICOERD proposed international classification of HRCT for occupational and environmental respiratory diseases had been tested, and evaluation of CT scans intra reader concordance had been investigated [30, 31]. Concordance between ILO-BIT criteria readings of radiographs and the results of CT scan readings by ICOERD criteria had been investigated [31, 32].

The goal of the present investigation was to evaluate if features of the imaging were coherent with a pneu-

Table 1
Patients with available diagnostic imaging, period of observation 2006-2013

Patients	n	Monolateral pleural plaques	Bilateral pleural plaques	Asbestosis-like parenchymal features	Negative imaging results	Uncertain or complex parenchymal features
Men	19	2	17	8	6	5
Women	6	2	4	2	3	1
All	25	4	21	10	9	6

Table 2

Patients with asbestosis-like parenchymal findings, period of observation 2006-2013

Patient ID	Age	Rx	CT scan	Parenchymal features	Other information of interest
Men					
3	80	X	X	Bilateral ground glass opacities	
6	73	X	X	Bilateral ground glass opacities; large opacities	Farmer
11	74		X	Bilateral ground glass opacities; honeycombing	Former farmer
14	76		X	Bilateral small opacities; profusion 2	Farmer
17	62		X	Linear bilateral interlobular opacities	Office worker
24	61	X	X	Left lung atelectasis parenchymal inhomogeneous attenuation with both irregular and rounded small opacities. Fibrotic bands in lower lung zones. A large opacity in the left lung. Vicarious emphysema of right lung and mediastinal shift	Retired post office employee. Heavy smoker. Hospitalized for aspiration pneumonia
26	55		X	Fibrotic bands in lower lung zones. Large opacity of the left lung. Emphysema of right lung	Farmer
32	50	X	X	Interlobular bilateral linear opacities; parenchymal inhomogeneous attenuation; bilateral ground glass opacities of lower lung zones	House painter
Women					
30	53		X	Bilateral ground glass opacities	
34	47		X	Bilateral ground glass opacities	

Table 3

Patients without asbestosis-like parenchymal findings, period of observation 2006-2013

Patient ID	Age	Rx	CT scan	Parenchymal features	Monolateral pleural plaques	Bilateral pleural plaques	Pleural calcifications
Men							
18	64		X	Mild emphysema	X		
19	66	X		CT suggesting old healed tuberculosis		X	X
23	61		X	No parenchymal damage		X	X
25	55	X		Mild emphysema		X	X
33	42	X		Increased broncho-vascular markings and hyperlucency of lung middle zones		X	X
37	43		X	No parenchymal damage		X	
Women							
16	69		X	No parenchymal damage	X		X
20	65	X	X	CT suggesting old healed tuberculosis		X	X
29	53		X	No parenchymal damage		X	X

moconiosis similar to asbestosis, so we were interested in a qualitative evaluation following the ILO-BIT and ICOERD criteria and we categorised the results of the panel reading in a simplified classification (pneumoconiotic features, not pneumoconiotic features and uncertain damages).

Our results underline that all the subjects reviewed, presented pleural plaques and this could be the main reason because code 501 (asbestosis) or 505 (pneumoconiosis) of 9th revision of ICD were utilized. However, ten subjects out of 25 showed imaging features similar to the asbestosis ones and in further six people presented insufficient but suggestive parenchymal abnormalities.

This appears to indicate that fluoro-edenite fibres inhalation can cause a pneumoconiotic disease similar to asbestosis.

Environmental exposures to asbestos and asbestiform fibres are, in general, considered not sufficient to cause pneumoconiosis even though several studies [27, 33-36] have reported the occurrence of lung fibrosis or pneumoconiosis in environmental contexts.

Occupational exposure to fibres in some cases might have been relevant, e.g., those related to earthmoving jobs in construction sites and in farming [37, 38]. In other cases (e.g., civil servants and housewives) environmental exposure circumstances should be hypothesized. Some similar-asbestotic patterns, furthermore, were observed in female patients in the total absence of conventional asbestos exposures.

The points of strength have already been introduced: a multidisciplinary study group, encompassing clinicians, epidemiologists, and public health profession-

Table 4

Patients with asbestosis-like parenchymal findings not sufficient for a diagnosis, period of observation 2006-2013

Patient ID	Age	Rx	CT scan	Parenchymal features	Monolateral pleural plaques	Bilateral pleural plaques	Pleural calcifications	Other information of interest
Men								
8	73		X	Bilateral parenchymal inhomogeneous attenuation not sufficient quality of CT scan	X		X	Smoker
15	74		X	Available previous CT not related with hospitalization. Second CT not available with a detailed report in medical records		X	X	Former farmer
22	68	X	X	Rx series in one single projection. CT not available parenchymal thickening and undetermined pulmonary fibrosis		X		
27	59		X	Suggesting ground glass opacities. Obesity not sufficient quality of CT scan				
35	48		X	Available CT not related with hospitalization. Second available CT without parenchymal window. Right lung parenchymal opacity suggesting rounded atelectasis		X	X	Heavy smoker. Former policeman
Woman								
10	76	X		Rounded opacities right lung parenchymal opacity in lower lung zone. Indicative CT imaging of not sufficient quality	X		X	

als, has had the opportunity to exhaustively explore the case-series of Biancavilla patients affected by pleural plaques and pulmonary fibrosis, isolating a group of them characterized by environmental exposure to fluoro-edenite in the absence of asbestos exposure.

This observation supports the notion of fluoro-edenite's fibrogenicity for residents in the area at study.

Three main limitations require to be mentioned as well. The study, for feasibility aspects, could not include a proper reference population, the information on environmental and occupational (or para-occupational) exposure to fluoro-edenite or other risk factors and confounding factors was unavoidably heterogeneous, and the low number of study subjects determined an overall low statistical power of the study. Notwithstanding these limitations, though, the study detected in Biancavilla a cluster of cases of a lung fibrosis similar to asbestosis, in addition to several cases of pleural plaques.

Fluoro-edenite capacity to induce fibrosis or pneumoconiosis was not specifically investigated and these results suggest the need of *in vivo* and *in vitro* experimental studies.

Regarding public health issues, further efforts are required to investigate respiratory conditions in Biancavilla residents through systematic prospective studies and examining in depth individual ways of exposure.

Even if recognizing the need for a continuing process of health surveillance and epidemiological monitoring in Biancavilla, the study findings can since now actively contribute to priority setting in environmental remediation, as extensively discussed in the WHO report "Urban redevelopment in contaminated sites"

[39] that includes a case study on Biancavilla, an area recognized since 2001 as National Priority Contaminated Site. The major effort supported by both National and Sicilian Regional Governments in order to reduce airborne fibre level is justified in light of both the well-recognized mesothelioma risk in this community and the emerging risk of environmental fibrosis and pneumoconiosis. The promotion of experimental, clinical, and epidemiological studies, together with the advancement of environmental clean-up, will also contribute to the most needed development of environmental health literacy and consequent resilience in the community.

CONCLUSIONS

In our clinical records, in addition to bilateral calcified pleural plaques, asbestosis-like parenchymal features were observed in patients' residents in Biancavilla town and without known occupational exposure to asbestos. These findings underline the requirement of further studies on the resident population to estimate their respiratory health, identify possibility of pneumoconiosis cases and the prevalence of pleural plaques and parenchymal impairment. The fibrogenic potential of fluoro-edenite fibres have to be tested by specific experimental studies.

Authors' contributions

Conceptualization: CB, PC, SS. Data curation: CB, AZ. Formal analysis: CB, AZ. Investigation: CB, RDS, VR, MLR, AC, PC, GDM. Methodology: CB, VR, GDM, PC. Project administration: CB, RDS. Resources: RDS, DM, VR, AC, SS. Supervision: CB, PC, AZ.

Validation: CB, PC, SS. Writing - original draft: CB. Writing - review & editing: CB, AZ.

Funding

This research was funded by “Sicily Regional Health Plan for Biancavilla Site of National Interest (SIN), Strategy Line n.2: Prevalence Surveys and implementation of diagnostic protocols” and carried out through a scientific cooperation between National Health Institute and Provincial Health Unit of Catania.

Institutional review board statement

The study was conducted in accordance with the Declaration of Helsinki of the World Medical Association and performed according to the rules of the “Decreto Legislativo n. 196/2003, Codice in materia di protezione dei dati personali” (Legislative Decree n. 196/2003 Regulations on personal data protection). The name and all birth/personal data were anonymized and each subject had a code assignment.

Informed consent statement

Patient consent was waived due to reason: the study was a retrospective survey of anonymized medical and imaging records of patients previously discharged from several different hospitals.

Data availability statement

Data supporting reported results are archived in regional hospitalizations datasets and motivated request is needed to be obtained. Medical records and imaging are archived in hospitals involved in the study: only anonymized information can be given. Only anonymized data can be consulted.

Conflict of interest statement

The Authors declare no conflict of interest.

Received on 14 December 2022.

Accepted on 5 June 2023.

REFERENCES

- Di Paola M, Mastrantonio M, Carboni M, Belli S, Grignoli M, Comba P, Nesti M (Eds). La mortalità per tumore maligno della pleura in Italia negli anni 1988-1992. Roma: Istituto Superiore di Sanità; 1996. (Rapporti ISTISAN, 96/40), p. 1-30.
- Paoletti L, Batisti D, Gianfagna A, Mastrantonio M, Nesti M, Comba P. Unusual high incidence of malignant pleural mesothelioma in a town of eastern Sicily: an epidemiological and environmental study. *Arch Environ Health*. 2000;55:392-8. doi: 10.1080/00039890009604036
- Gianfagna A, Oberti R. Fluoro-edenite from Biancavilla (Catania, Sicily, Italy): Crystal chemistry of a new amphibole end-member. *Am Mineral*. 2001;86:1489-93.
- Comba P, Gianfagna A, Paoletti L. Pleural mesothelioma cases in Biancavilla are related to a new fluoro-edenite fibrous amphibole. *Arch Environ Health*. 2003;58:229-32. doi: 10.3200/AEOH.58.4.229-232
- Soffritti M, Minardi F, Bua L, Degli Esposti D, Belpoggi F. First experimental evidence of peritoneal and pleural mesotheliomas induced by fluoro-edenite fibres present in Etnean volcanic material from Biancavilla (Sicily, Italy). *Eur J Oncol*. 2004;9:169-75.
- Belpoggi F, Tibaldi E, Lauriola M, Bua L, Falcioni L, Chiozzotto D, Manservigi F, Manservigi M, Soffritti M. The efficacy of long-term bioassays in predicting human risks: mesotheliomas induced by fluoro-edenite fibres present in lava stone from Etna volcano in Biancavilla Italy. *Eur J Oncol*. 2011;16:185-95.
- Ballan G, Del Brocco A, Loizzo S, Fabbri A, Maroccia Z, Fiorentini C, Travaglione S. Mode of action of fibrous amphiboles: the case of Biancavilla (Sicily, Italy). *Ann Ist Super Sanità*. 2014;50:133-9. doi: 10.4415/ANN_14_02_05
- Bruno C, Tumino R, Fazzo L, Cascone G, Cernigliaro A, De Santis M, Giurdanella MC, Nicita C, Rollo PC, Scondotto S, Spata E, Zona A, Pietro Comba P. Incidence of pleural mesothelioma in a community exposed to fibres with fluoro-edenite composition in Biancavilla (Sicily, Italy). *Ann Ist Super Sanità*. 2014;50:111-8. doi: 10.4415/ANN_14_02_02
- International Agency for Research on Cancer. Fluoro-edenite. In: *Some nanomaterials and some fibres*. Lyon: IARC; 2017. (IARC monographs on the evaluation of carcinogenic risks to humans, 111). p. 215-42. Available from: <http://monographs.iarc.fr/ENG/Monographs/vol111/index.php>.
- Biggeri A, Pasetto R, Belli S, Bruno C, Di Maria G, Mastrantonio M, Trinca S, R Uccelli R, Comba P. Mortality from chronic obstructive pulmonary disease and pleural mesothelioma in a natural fibre (fluoro-edenite) contaminated area. *Scand J Work Environ Health*. 2004;30:249-52. doi: 10.5271/sjweh.786
- Cernigliaro A, Fano V, Pollina Addario S, Caruso S, Penisi P, Forastiere F, Perucci CA, Comba P, Scondotto S. Mortality and hospital discharges in the population of Biancavilla (Sicily) contaminated by natural fibres. *Epidemiol Prev*. 2006;30:227-31.
- Achille Cernigliaro, Antonello Marras, Sebastiano Pollina Addario, Salvatore Scondotto, Daniela D'Ippoliti, Erica Santelli, Paola Michelozzi, Francesco Forastiere. Stato di salute della popolazione residente nelle aree a rischio ambientale e nei siti di interesse nazionale per le bonifiche della Sicilia analisi dei dati ReNCaM (anni 2004-2011) e dei ricoveri ospedalieri (anni 2007-2011) Rapporto 2012. Available from: <https://www.salute.gov.it/portale/temi/documenti/investimenti/29.pdf>.
- Pirastu R, Comba P, Conti S, Iavarone I, Fazzo L, Pasetto R, Zona A, Crocetti E, Ricci P (Eds). SENTIERI - Studio epidemiologico nazionale dei territori e degli insediamenti esposti a rischio da inquinamento: Mortalità, incidenza oncologica e ricoveri ospedalieri [SENTIERI - Epidemiological study of residents in national priority contaminated sites: Mortality, cancer incidence and hospital discharges]. *Epidemiol Prev*. 2014;38(Suppl 1):43-8.
- Zona A, Iavarone I, Buzzoni C, Conti S, Santoro M, Fazzo L, Pasetto R, Pirastu R, Bruno C, Ancona C, Bianchi F, Forastiere F, Manno V, Minelli G, Minerba A, Minichilli F, Stoppa G, Pierini A, Ricci P, Scondotto S, Bisceglia L, Cernigliaro A, Ranzi A, Comba P; Gruppo di lavoro SENTIERI; Gruppo di lavoro AIRTUM-SENTIERI; Gruppo di lavoro Malformazioni congenite-SENTIERI. SENTIERI: Studio epidemiologico nazionale dei territori e degli insediamenti esposti a rischio da inquinamento.

- Quinto Rapporto [SENTIERI: Epidemiological Study of Residents in National Priority Contaminated Sites. Fifth Report]. *Epidemiol Prev.* 2019;43(2-3 Suppl 1):1-208. doi: 10.19191/EP19.2-3.S1.032. Erratum in: *Epidemiol Prev.* 2019 Jul-Aug;43(4):219.
15. Rapisarda V, Ledda C, Ricceri V, Arena F, Musumeci A, Marconi A, Fago L, Bracci M, Santarelli L, Ferrante M. Detection of pleural plaques in workers exposed to inhalation of natural fluoro-edenite fibres. *Oncol Lett.* 2015;9:2046-52. doi: 10.3892/ol.2015.2978
 16. Ledda C, Pomara C, Bracci M, Mangano D, Ricceri V, Musumeci A, Ferrante M, Musumeci G, Loreto C, Fenga C, Santarelli L, Rapisarda V. Natural carcinogenic fiber and pleural plaques assessment in a general population: A cross-sectional study. *Environ Res.* 2016;50:23-9. doi: 10.1016/j.envres.2016.05.024
 17. International Labour Office. Guidelines for the use of the ILO international classification of radiographs of pneumoconioses (Revised edition 2011). Geneva: ILO; 2011. (Occupational safety and health series, 22). Available from: https://www.ilo.org/wcmsp5/groups/public/---ed_protect/---protrav/---safework/documents/publication/wcms_168260.pdf.
 18. Wolff H, Vehmas T, Oksa P, Rantanen J, Vainio H. Asbestos, asbestosis, and cancer, the Helsinki criteria for diagnosis and attribution 2014: recommendations. Consensus Report. *Scand J Work Environ Health.* 2015;41:5-15. doi:10.5271/sjweh.3462
 19. World Medical Association. WMA Declaration of Helsinki - Ethical principles for medical research involving human subjects, adopted by the 18th WMA General Assembly, Helsinki, Finland, June 1964 and successive amendments. Available from: <https://www.wma.net/policies-post/wma-declaration-of-helsinki-ethical-principles-for-medical-research-involving-human-subjects/>.
 20. Glazer CS, Newman LS. Occupational interstitial lung disease. *Clin Chest Med.* 2004;25:467-78. doi: 10.1016/j.ccm.2004.04.004
 21. Gräsel B, Kaya A, Stahl U, Rauber K, Kuntz C. Erionite-induced pleural plaques. Exposition to urban pollution in a female Turkish migrant in Germany. *Der Chirurg.* 2008;79:584-8. doi: 10.1007/s00104-008-1515-9
 22. Kliment C.R, Clemens K, Oury TD. North American erionite-associated mesothelioma with pleural plaques and pulmonary fibrosis: a case report. *Int J Clin Exp Pathol.* 2009;2:407-10.
 23. Ministero del Lavoro, della Salute e delle Politiche Sociali. Classificazione delle malattie, dei traumatismi, degli interventi chirurgici e delle procedure diagnostiche e terapeutiche. Versione italiana della ICD-9-CM. https://www.salute.gov.it/imgs/C_17_pubblicazioni_2251_allegato.pdf.
 24. CDC National Center for Health Statistics. International Classification of Diseases, Tenth Revision (ICD-10). <https://www.cdc.gov/nchs/icd/icd10.htm>.
 25. Rey F, Boutin C, Steinbauer J, Viallat JR, Alessandrini P, Jutisz P, Di Giambattista D, Billon-Galland MA, Hereng P, Dumortier P, De Vuyst P. Environmental pleural plaques in an asbestos exposed population of northeast Corsica. *Eur Respir J.* 1993;6:978-82.
 26. Sichletidis L, Daskalopoulou E, Chloros D, Vlachogiannis E, Vamvalis C. Pleural plaques in a rural population in central Macedonia, Greece. *Med Lav.* 1992;83:259-65.
 27. Metintas M, Metintas S, Hillerdal G, Ucgun I, Erginel S, Alatas F, Yildirim H. Nonmalignant pleural lesions due to environmental exposure to asbestos: a field-based, cross-sectional study. *Eur Respir J.* 2005;26:875-80. doi: 10.1183/09031936.05.00136404
 28. Sullivan PA. Vermiculite, respiratory disease, and asbestos exposure in Libby, Montana: Update of a cohort mortality study. *Environ Health Perspec.* 2007;115(4):579-85. doi: 10.1289/ehp.9481
 29. Regione Sicilia. Decreto 6 maggio 2016. Approvazione del Protocollo sanitario regionale standardizzato per gli accertamenti sanitari in materia di amianto. *Gazzetta Ufficiale della Regione Siciliana* n. 23, 27 maggio 2016. Available from: https://olympus.uniurb.it/index.php?option=com_content&view=article&id=15757:sic6-5-16&catid=27&Itemid=137.
 30. Suganuma N, Kusaka Y, Hering KG, Vehmas T, Kraus T, Parker JE, Shida H; International CT Classification Study Group. Selection of reference films based on reliability assessment of a classification of high-resolution computed tomography for pneumoconioses. *Int Arch Occup Environ Health.* 2006;79(6):472-6. doi: 10.1007/s00420-005-0067-2
 31. Suganuma N, Kusaka Y, Hering KG, Vehmas T, Kraus T, Arakawa H, Parker JE, Kivisaari L, Letourneux M, Gevenois PA, Tuengerthal S, Crane MD, Shida H, Akira M, Henry DA, Nakajima Y, Hiraga Y, Itoh H, Hosoda Y. Reliability of the proposed international classification of high-resolution computed tomography for occupational and environmental respiratory diseases. *J Occup Health.* 2009;51:210-22. doi: 10.1539/joh.l8030
 32. Tamura T, Suganuma N, Hering KG, Vehmas T, Itoh H, Akira M, Takashima Y, Hirano H, Kusaka Y. Relationships (I) of International Classification of High-resolution Computed Tomography for Occupational and Environmental Respiratory Diseases with the ILO International Classification of Radiographs of Pneumoconioses for parenchymal abnormalities. *Ind Health.* 2015;53(3):260-70. doi: 10.2486/indhealth.2014-0073
 33. Baris YI, Sahin A, Ozesmi M, Kerse I, Ozen E, Kolacan B, Altinörs M, Göktepe A. An outbreak of pleural mesothelioma and chronic fibrosing pleurisy in the village of Karain/Ürgüp in Anatolia. *Thorax.* 1978;33(2):181-92. doi: 10.1136/thx.33.2.181
 34. Baris YI, Artvinli M, Sahin AA, Sebastien P, Gaudighet A. Diffuse lung fibrosis due to fibrous zeolite (erionite) exposure. *Eur J Respir Dis.* 1987;70:122-5.
 35. Dumortier P, Göcmen A, Laurent K, Manço A, De Vuyst P. The role of environmental and occupational exposures in Turkish immigrants with fibre-related disease. *Eur Respir J.* 2001;17:922-7. doi: 10.1183/09031936.01.17509220
 36. Lampert Naik S, Lewin M, Young R, Dearwent SM, Lee R. Mortality from asbestos-associated disease in Libby, Montana 1979-2011. *J Expo Sci Environ Epidemiol.* 2017;27(2):207-13.
 37. Massaro T, Baldassarre A, Pinca A, Martina GLM, Fiore S, Lettino A, Cassano F, Musti M. Esposizione ad amianto in edilizia in aree della Basilicata caratterizzate dalla presenza di rocce contaminate da tremolite [Exposure to asbestos in buildings in areas of Basilicata characterized by the presence of rocks containing tremolite]. *G Ital Med Lav Ergon.* 2012;34(3 Suppl):568-70.
 38. Massaro T, Dragonieri S, Martina GLM, Baldassarre A, Cassano F, Musti M. Amianto e agricoltura: nuove prospettive di rischio [Asbestos and agriculture: new perspectives of risk]. *G Ital Med Lav Ergon.* 2012;34(3 Suppl):581-2.
 39. World Health Organization Regional Office for Europe. Urban redevelopment of contaminated sites: a review of scientific evidence and practical knowledge on environmental and health issues. Copenhagen: WHO Regional Office for Europe; 2021.